

A Method for Preparation of Frozen Sections

Dr. Stephen Peters Pathology Innovations, LLC

The basics

Start with a sharp blade

I find that I always get my best quality section with a new sharp blade. I think some of the places we try to save money in medicine are a bit "pound foolish". Your patients surgery is costing thousands of dollars. Hundreds of dollars are spent on disposables including lap pads, gloves, sponges, drapes, cautery, needles, needle magnets, BP cuff, IV tubing, We are conserving pennies on what may be the most important decision impacting on the procedure. Yet some will risk quality by trying to get "20 shaves" out of a **disposable** blade.

In my practice I treat every patient to a new section of blade. I will change it as soon as my section quality begins to fall. Some tissues such as tough collagenous tissues or calcified tissues will quickly dull the blade. If I'm having trouble getting a good section with a new blade on occasion I have changed to a second new blade and easily prepared a quality section.

Safety Tip

If you cut yourself on a blade used on only one patient, you will have minimized your risk of transmittable disease. If you cut yourself on a blade that has been used for days, it is like sleeping with numerous partners.....without the fun! In this day and age of doing FNA's with ridiculously flexible long safety needles and using annoying safety scalpels we can justify using a sharp blade for safety reasons.....and get the benefit of awesome frozen sections every time!

Sitting or standing

I always sit on a stool when I cut. I am hoping you learn to use the brush as an articulate fine instrument, capable of the delicately maneuvering of a microscopically thin snowflake of tissue **while in flight!** Why would you want to do this hunched over with your neck hyper extended? This position is fine if you are bending over to look in a hole in fear of an animal jumping out at you! But for cutting a frozen section you want to be relaxed and comfortable so that you will have maximum control in your left hand.

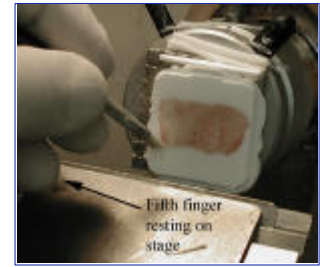
The Brush

I'm a brush user. I believe everyone must first learn to be good with a brush. I consider starting a student on the anti-roll device like putting a child on crutches before they learn to walk. The purpose of the brush is to grab and maneuver the section across the stage. Unless you have perfect temperature, a cold section will by nature try to curl up and pull away from the brush. For this reason I use a brush with stiff bristles and a fairly wide gripping surface. I have found Chinese boar bristles to be the stiffest and work the best for me. You can buy and 1/4 inch #2 flat or bright brushes from an art supply store for about \$3 and cut them at an angle. With this angled tip, the brush meets the tissue flat like a broom because the brush is held at an angle. I never understood why anyone would want to use the flimsy camel hair brushes. The section can easily pull away from these flexible hairs.



Holding the brush

Hold the brush like a pen in the left hand and stabilize the hand by gently resting the side of the fifth finger on the stage (or where ever you can find a place depending on your cryostat). This gives the operator great dexterity and allows for conservation of movement. Focus on developing your dexterity so you can control the brush like a fine instrument. Could you catch a snowflake as it is falling? I cut the brush at an angle, which approximates the angle I hold the brush in my hand. This results in the brush meeting the tissue flat over its 1/4 " length.



Turning the wheel

Turn the wheel in a continuous uniform motion without hesitation. I have seen many frozen sectionists using a brush stop at the beginning of the section, slowly grab the tissue and then start to turn the wheel. In my experience this practice adds to potential artifacts at the beginning of the section, potential variations in thickness, and leads to difficulties when approaching tissues containing fat. With practice, by holding the brush as I described, the operator is capable of grabbing the tissue in a continuous motion, which began before the tissue meets the knife and continues through the complete section. .


Movement of the brush

As the block begins to move toward the knife the brush moves downward in pace with the block. The brush can **gently** rest on the bottom 2mm of the block and "ride the block" pulling away just as the block meets the knife. It is the downward movement of the brush that allows you to keep a continuous motion as you grab the section.

It is like handing off a baton in a relay race. The second runner must run along side the first runner for the handoff. The baton never slows down. If the second runner was stopped the first runner would have to slow to a stop and the second runner would have to accelerate with the baton again.

As the first few millimeters of the section passes the knife there will be some degree of curling of the section. As the curl begins, the brush in motion will catch the edge of the tissue and change to a horizontal motion toward you . The path of the brush is an "elbow" shape down and then toward you in a continuous motion. It is important to pull the tissue toward you rather than to press it to the cryostat stage. Pressing tissue to the cryostat stage sometimes result in adhesion of the tissue to the stage, especially if the tissue is fatty. This will result in a smeared section and a need to clean the stage. This motion of grabbing the tissue is like pulling a blanket over you in bed. As the brush returns to grab the next section it completes a continuous elliptical motion. ***The continuous repeated sectioning of a block becomes like turning the pedals of a bicycle.*** Both hands are circling in synchrony.

Having blocks prepared with a "**handle**" of embedding medium makes this job easier without having to engage the tissue with the brush.



1) As the block descends toward the brush the brush keeps pace with the block by gently resting on the bottom 2-3 mm of the block and "***Riding the block***"

2) As the block meets the blade and the sections begins it's curl the brush leaves the block while catching the curling edge of the section. "***Catching the curl***"

3) The brush jumps off the block with the curl. "***The brush jumps over the blade***"

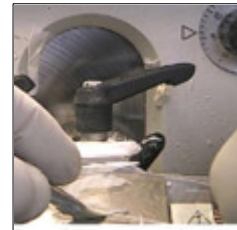
3) The brush holding the curl pulls the section horizontally over the stage like a pulling the covers over you in bed without pressing the tissue to the stage. "***Pull over the blanket***"

Retrieving the section

Tissue can be picked up from the cryostat stage or from the block. I routinely pick sections up from the stage. When the section is complete the tissue can be picked up by holding the slide just above the section and angle the slide down to touch a portion of the tissue. Static attraction will draw the section to adhere to and quickly melt on to the warm slide. Having a few millimeters "handle" of embedding medium surrounding the tissue is an advantage. This extra medium allows a margin of error for curling or flipping at either end before it involves the tissue. If I am having particular difficulties with the section I can stop the section before the last 2 mm. of embedding medium leaving the section attached to the block. This allows a fixed edge of the section against which to stretch the section with the brush. Occasionally when faced with a difficult situation I may have more luck retrieving the section from the block. This can sometimes offer a solution to problems arising from curling or fat sticking to the stage. Some operators prefer this technique for the majority of their sections. To retrieve from the block the tissue is cut through and stopped when the handle of medium on the far side of the tissue is reached. At this point the crank is moved backward and the block is reversed away from the knife. The section is uncurled downward with the brush over the face of the block and the section is picked up off the block face rather than the stage .



Retrieving from stage

Slide levers down to gently touch the section which will float onto the slide with static or cohesive attraction. Try avoid stretching or folding the section during this process by keeping the a steady hand and the transverse axis of the slide parallel to the section.



Retrieving from the block

- 1) A section is cut leaving an attachment of medium at the top
- 2) The wheel is turned in opposite direction bring the section back to the face of the block.
- 3) Section is retrieved from the block

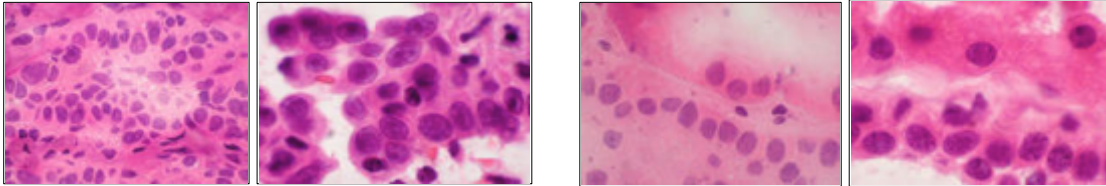


Rapid fixation

As I mentioned earlier I hold the slide in my right hand as I turn the wheel. The moment the section is complete, I immediately pick up the tissue on the slide and in a moment it is placed into fixative.

Have your fixative opened in an immediately reachable location. Start with the slide in your hand. If I am using a staining rack I keep it outside the fixative jar so it does not impede my swift motion. I first fix the slide in 95% etoh then put it in the rack

If there is delay in fixing the tissue there will be significant-drying artifact. In my experience when the frozen section is sitting cold on the stage the effect of drying is minimal. From the time the tissue touches a warm slide it starts to undergo significant drying artifact with loss of nuclear detail and leakage of fluids from the cytoplasm. The examples below show the same tissue after 15 seconds delay of fixation on a warm slide and sections fixed immediately. The differences are striking. It also demonstrates the quality of cytology possible by frozen section using this system.



- 1) Bronchiolo-alveolar Carcinoma -15 seconds drying
- 2) Same tissue immediately fixed 95% ETOH

- 1) Kidney tubules -15 seconds drying
- 2) Same tissue immediately fixed in 95% ETOH

Thickness of the section

For general surgical pathology I recommend cutting at six microns. This thickness will give a rich stain, which is easier to interpret at scanning powers of 2x and 4x where pathologists gather much of their information. Very thin sections will often look pale at these powers and fine details are easy to miss. A six micron section will afford a moment more time to avoid drying artifact. There will also be less nuclear "holes" visible from ice crystal artifact.

Specialized situations may call for thinner or thicker sections.

Thickness must be confirmed visually. In FS technique III I will show sections of various thicknesses. In my experience cryostats will not repeatedly cut perfect six micron sections unless all conditions are correct and the sections are being cut repeatedly in uniform motion. The change of surface temperature of the block resting between sections will result in warming and expansion and a thicker section will be cut. It is for this reason that the first section cut from a block is often thicker. When warmed with the hand the first section will often be thicker. When cutting I always let the first section pass then continue on to take to the next section if it appears to be the correct thickness. This is another reason why we want to become skilled with the brush so that we can continuously cut the sections until we are satisfied that we have a section of the correct thickness without other artifacts.

Staining the sections

Individual staining recipes are a matter of pathologist preference. My only advice is not to rush any step of the staining process and to keep all stains and solutions fresh and well maintained. Gentle agitation is helpful in speeding the process and keeping the staining uniform, but the type of tissue and its adhesive nature should be considered (see below).

When staining I find that looking at the slide after it leaves the bluing agent is a good way to assess the adequacy of the stain.

Get to know the color and shade of a well stained slide as compared to a lightly stained slide. In our hematoxylin I look for a specific navy blue tone to tell me it is stained well. Keep in mind the thickness of the tissue and the amount of nuclear material will make the slide appear lighter or darker. However there is a particular tone of blue that tells me the slide is well stained. Make your own observations. The idea is to check the slide before continuing on with the staining.

I like many pathologists make the large part of my observations at scanning powers i.e. 2x or 4x magnification. At these powers looking at an under stained slide is like driving in a snowstorm, you really don't see much. When looking at lymph nodes for metastatic disease I give particular attention to deep rich staining, especially the eosin. If the eosin stain is rich, the pale pink cytoplasm of a sinus histiocyte can be more easily distinguished from the tumor cell cytoplasm which may be more eosinophilic or more clear.

Why did my tissue fall off?

I'm not sure what the scientific explanation for the adhesion of tissue to the glass slide but I would guess it has something to do with weak bonding at a molecular level conveyed by the fluids in the fresh tissue to the glass. Anyone who knows the explanation please let me know. I arrived at this explanation because in my experience the dryer the tissue the less tendency it has to adhere and if it has been in formalin it seems to have had any tendency to adhere "washed away"; the "juicier" tissues adhere better. I like to think of them as having "**more glue**". In my experience I can list several situations where I have experienced sections coming off the slide in the staining process. Obviously over agitating loosely held tissues will shake then off.

- 1) Very dry tissues either by nature or desiccation.
- 2) Large ratio of perimeter to area. Thin strips that have a large perimeter to catch the turbulence of the motion in the stain jars can easily fall off the slide. This is especially true if thin fibrous walled cysts which are not very "juicy" tissues to begin with. Also included in this are amorphous necrotic tissues which have nothing holding them together. This also applies to very thick sections which have a thicker wall to grab the turbulence.
- 3) Ammonia bluing reagent is too concentrated. If you use ammonia for bluing my rule is if I can smell it without putting my nose up too it is too strong.
- 4) 100 % Etoh instead of 95%. I have on occasion had someone place 100% Etoh in my fixing jar instead of 95%. In my experience this will not stay on the slide.

5) A section is placed over embedding medium which is already on the slide. When placing multiple sections on a slide be careful to not overlap the tissue onto the embedding medium of the neighboring section.

Orienting the tissue to the knife

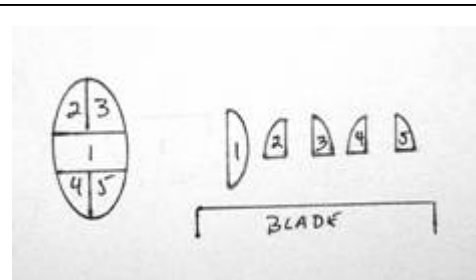
This is an extremely important aspect of the frozen section preparation. Using the embedding system described in the previous articles it is quite easy to prepare and orient tissues in the wells so that the knife meets the tissue in a specific orientation. Based on my experience I have come up with certain rules I try to follow:

1) ***Fat should be the last thing to hit the blade or should hit the blade by itself*** whenever possible. Fat does not get hard enough to cut well at temperatures that are best for cutting most other tissues. When fat hits the blade before the more manageable tissues it may smear and ruin the rest of the section. I find by hitting the knife last or by itself fat won't interfere with the other tissues as much. Sectioning fat will be discussed in greater detail below. If I find myself having difficulty getting a good section because fat appears in the plane I suggest rotating the chuck to avoid the fat or try "***The Gouge***".

2) The most critical aspect of the tissue should be perpendicular or diagonal to the blade and not the first or last aspect of the tissue to hit the blade. Let's consider a section as having a beginning, middle, and an end. At the beginning there is a risk of curling, or brush damage, possibly thickness issues because hesitation engaging the tissue. These are opportunities for artifacts. Similarly at the end curling becomes an issue and possibly stretching in picking up the tissue. The middle is the place where we are less likely to see artifacts and have the cleanest histology. This is where I want to see that critical portion of the slide such as an inked margin.

3) Epithelial and mucosal lined tissues such as skin and GI, bladder, uterus and cervix should be oriented with the plane of the epithelium perpendicular to the blade.

When embedding a skin ellipse the end which hits the blade first has a tendency to curl. This diagram below shows an approach to embedding a small skin ellipse, so that the longitudinal margins (2-5) will hit the blade last. This arrangement is quite simple to do using specimens prepared by frozen block cryoembedding.



Skin Embedding Tip: Karen Courtney of Metropolitan Methodist Hospital, San Antonio Texas embeds skins *epidermis to epidermis*. Karen agrees that skin should be embedded vertically. When cutting skin the medium does not adhere to the epidermis. I believe the outer later of squamous cells in the stratum corneum which are designed to "flake away" from our skin, simply come apart from the rest of the epidermis. The result is that we see a separation of the epidermis from the medium. This is one way to tell if you have reached the level of the epidermis when you are trimming. By embedding "epidermis to epidermis" these lines of separation will be gathered together and result in the instability of the section over a narrow range. The rest of the skin will have its own channels of preservation.

Please, always start with a sharp blade!

I am sure others may not agree with these suggestions and may have other ideas on this subject. We all learn so much of this in our own experience. The point I am trying to make is to consider the outcome as a result of how the tissue meets the blade. This system will allow you to arrange the tissue however you would like to.

How much tissue can be put in a single block?

The amount of tissue that can be cut in a single block depends on two factors.

1) The ability of the cryostat to cut through large tough portions of tissue.

In order to get a smooth evenly cut section the knife must pass freely through the tissue with no movement, stretching, loosening or bending of any part of the mechanism that holds the chuck and tissue and the blade. This implies that the chuck is tightly secured and that any shafts or supports that hold the chuck are sound. The blade, the blade holder and any structure that holds the blade holder in place must be secured and tight. This ability will vary with makes and models of cryostat and with the state of maintenance of a given cryostat. The type of blade and the flexibility of the blade are another factor.

2) The toughness or hardness of the tissue.

Tissues vary considerably in toughness or hardness. On my cryostat tissues such as liver or kidney can be easily cut even in very large pieces. But very tough collagenous tissues like scalp or cervix will cut thick and thin if too large a section is attempted. The colder these tough tissues are the more difficult they are to cut. So before taking a very large panoramic portion of tissue for a frozen section, consider the consistency of the tissue.

When the system is being stressed by too much tissue resistance I have observed the phenomenon of thick and thin sections. This happens when the stress moves the knife to take a thicker section. The following section will then be thinner.



When cutting very tough tissues keep the tissue block as warm as you can and still get a section.

Listen to the blade

Get to know the sound of a good frozen coming off the blade. There is almost no sound at all. When a block is too cold there is distinct sound as the blade scratches the icy block. The blade will make a variety of grating or vibrating sounds when it is at the wrong blade angle, showing movement or out of positioned because of a bit of medium in the blade holder.

Trimming the block

This refers to the shaving away the surface of the block to a depth at which the complete desired tissue face is available for the frozen section. This rather important step is often taken for granted. If trimmed too little, the section will not include some critical feature, if trimmed too much there will be unnecessary wastage of tissue and potential loss of some precious portion of the sample. Two key skills must be developed to carryout this task. The operator must learn to grossly recognize the anatomy and landmarks visible on the block face. I refer to this as "***reading the block***". Although this is often a small picture to read grossly, one must be well aware when such things as the inked margin, the mucosal surface or the epidermis becomes available for the section. There is a brief period before these structures are reached when they look as though they have been reached. At this slightly "premature stage" it is like looking at the structure through frosted glass. One will think the structure is present but it will not appear in the section.

<p>This "premature face" must be learned to be distinguished from the "mature" face. The keratin layer of the epidermis has a tendency of separating from the embedding medium on the cut section and can serve as an indicator that the epidermis has been reached.</p>		<p>The tissue is fully exposed and seen as a crisp discrete line. This skin is dyed red on the epidermis and black in the deep aspect. It is much less apparent in less colorful samples. Look close!</p>	
--	---	---	---

Agar Depth markers

Ervin Shaw, M.D., of Pathology Associates of Lexington, P.A. has some ingenious suggestions for using layered blocks of colored agar as markers of depth and orientation in paraffin blocks. Markers are made by layering different colors of agar in a Petri dish at a quantitative thicknesses. Placing a depth marker level with the tissue face, one can approximate how deep they have cut into the tissue by the color of the agar. This technique could be applied to frozen section by placing a marker on the well floor. Knowing the thickness of the marker and the thickness of the tissue one can estimate how much tissue has been cut through. By preparing the colored layers in intervals at a fraction of a mm. it could be a useful in estimation the depth of very thin specimens. See more at Dr Shaw's site: <http://www.palpath.com/agards.htm>

The well adjusted cryostat

Pathologists, residents, PA's and histotechs should have a basic knowledge of maintenance of their cryostat. It is a good idea to read the manual. This should include:

Lubrication- where and when to apply oil periodically and especially after warming and decontamination. Oil must be formulated for cryostat temperatures.

Blade angle- This varies with make of cryostat and type of blade. Be aware of the proper setting for your cryostat and how to adjust it. It is not uncommon for a cryostat to be left out of adjustment by some covering tech, service person, new resident etc. You will be faced by a strange sound and poor sectioning.

X-Y Axis

To achieve the ideally trimmed block the path of the plane of the face of the block must be in the same plane as the blade. If these planes are parallel then trimming will start uniformly across the block face. Using face down embedding in wells, the ability to prepare blocks with faces parallel to the chuck face becomes a reality. In a **properly adjusted cryostat** these flat surfaces can be reached with minimal trimming and yield a complete section with minimal trimming and wastage. But how do we "properly adjust" our cryostat? Here is where our technology has left something to be desired. Many cryostats designed and priced for used in the clinical laboratory offer only rudimentary manual adjustability of the "X-Y" axis. Some are totally stationary. Therefore in order to adjust the block face to the plane of the knife blade it is a difficult coarse adjustment. In order to achieve the flat minimally trimmed block faces such as seen in the sesame seed art in the earlier articles, painstaking fine adjustments need to be accomplished to reach the entire plane of sesame seeds before cutting through any. If you need this degree of alignment be aware that manually moving these chuck holders even a degree will result in a drastic change in the way the knife meets the block. Ideally, using the embedding wells and preparing blocks to optimize "parallel faces" then an initial adjustment to the cryostat to meet the center of the block will yield the least possible trimming.

Keep It Clean

I believe we should leave the cryostat clean after each use. It takes seconds to empty the shavings tray and wipe out the loose shavings with a gauze. There are many who feel cleaning the shavings once a day by a "histo-slave" is adequate cryostat hygiene. Having personally inhaled shavings from a cryostat snowstorm I cannot agree. I think a filthy cryostat offers several risks:

- 1) Risk of infection by inhalation or other route of entry.
- 2) Risk of cross contamination of a slide with an aberrant section.
- 3) If tissue or a chuck is dropped into a snowstorm it comes up looking like its covered in coconut.

I think we should leave the cryostat the same way we leave the bathroom. We do not wait for our mother to come flush for us!or do we?

Clean your brushes When the frozen section brush gets dirty there is a greater tendency for the sections to cling to the brush. They can be cleaned in seconds by:

- 1) quick touch of soap and water and dry
- 2) quick dip and dry in 100% ETOH

- 3) quick dip and dry in xylene.
- 4) cool for a few seconds against a cold surface.

Temperature of the block

There is an ideal temperature for cutting the frozen section block. After years of research I find this to be exactly in between too cold and too warm. This is the magical temperature when the section cuts such that it flows over the knife in a smooth uniform sheet with minimal curling. At this perfect combination of temperature, tissue type and a sharp blade sections can float off without even using a brush. A block that is too cold will quickly curl in an unmanageable way or shatter creating a Venetian blind like artifact. If the tissue you're cutting is very tough when it is very cold it will be tougher and further stress the system, resulting in thick and thin sections. When the block is too warm it will bunch in a crumpled pile.

To warm a cold block many operators including myself will place the thumb on the face of the block. Just bare in mind that many an operator has also cut his finger on the knife blade this way. When using any part of the hand to touch the block, always turn the crank to bring the block as far from the blade as possible and be very careful. You should even have the wheel locked or be well aware that if you apply downward motion to the block it may take your thumb on a ride to meet the blade!!.

I find I must watch new residents like a hawk at the beginning of all stages the frozen section process. They will do some pretty scary things around the knife blade and with a scalpel for that matter.

To cool a warm block using the apparatus in the precision cryoembedding system, simply press the over-chuck freezing block to the block face for a few seconds. In most cryostats there is some kind of heat extractor that can be used in a similar way. There are freezing sprays available to rapidly cool blocks. These can be useful for super-cooling fat. Be careful to avoid breathing these sprays or any shavings that may be aerosolized in the cryostat. If you have a snowstorm in your cryostat these sprays will turn it into a blizzard!




My usual routine is to trim the block. I then try a section. If it needs warming I place the thumb on the tissue for about two seconds. I then take a quick turn of the crank, brush that section away and pick up the next section on the slide. I find the first section after warming is will usually be too thick. If you follow this routine please know your cryostat and learn how to do this and avoid the blade.

Looking at the section

This refers to looking at the actual section as it flows over the knife. If you can tell a good section from a bad section at this stage you will know to go back for another cut. This is better than finding out you have a miserable section when you're reading the slide.

1) Too thick , too thin or just right

If your lucky enough to have a cryostat that always cuts the exact thickness no matter what the state or type of tissue or what the condition of the cryostat then skip this section. For the rest of us who find a variety of tissue thickness magically appearing despite the cryostat thickness setting it's important to recognize the thickness of the section. A section that is too thin will have a more translucent lens paper like quality. A section that is too thick will look almost opaque and seem a bit less flexible. To my eye a 5 or 6 micron section looks about like a thin printer paper.



Three microns thick

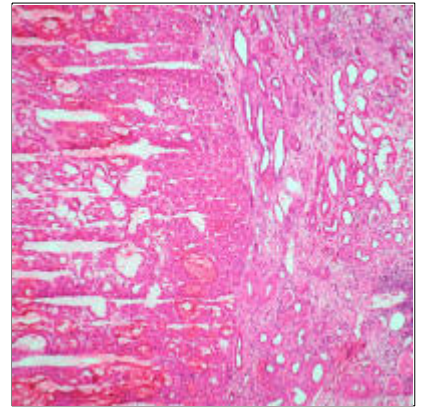
Six microns thick

Ten microns thick

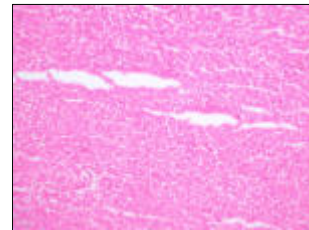
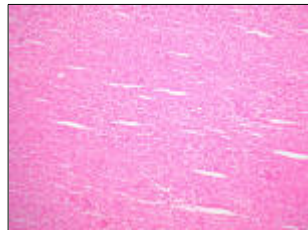
2) Shattering

This artifact is often a result of the block being too cold. It can be dealt with by warming the block. Tissues with high water content have greater tendency to shatter and must be warmed to a temperature that will cut with the least shattering. Edematous or bloody tissues will show this problem. Brain biopsies are notorious for this problem. Imagine trying to cut an ice cube. It will shatter as it is cut.

This kidney tumor is a good example of water content causing shattering. The tumor tissue on the left is shattering while the benign kidney on the right is cutting without shattering. I believe the tumor has a higher water content and becomes harder and icier when frozen at the same temperature.



Notice the regular periodicity of the shattering. I believe the shattering process can be likened to a piece of wet cloth which has frozen. If one pushed a wedge (blade) under the cloth it would bend. The icy sheet which forms would break periodically as the wedge pushed under it. Each successive break would represent the ice passing its limit of flexibility. You can only bend a sheet of glass so far without breaking it.



The shattering is obvious in the three pictures in the top row.

Shattering is very subtle in the pictures in the bottom row. You have to look very closely to see this shattering. You may be able to feel it or hear it as its cutting if you pay close attention.

3) Stripes on the section


Nicks on the blade.

Thin stripes perpendicular to the blade can be a sign of nicks on the blade. This can result from cutting tissues with calcification, suture or staples.



Tissue adhering to the underside of the blade

Wider stripes, taring or mysterious sudden difficulty cutting the tissue can be a result of tissue adhering to the underside of the blade. This is common in fatty tissues. The blade will have to be removed and wiped when this happens. Be extremely careful when wiping the blade. Always try to wipe perpendicular to and away from the edge of the blade to avoid being cut.



4) Wavy lines "Chatter"

This is a sign of movement in the system and possibly a cry for servicing. I see these fine regularly spaced lines in my cryostat when there is movement in the blade because there is movement in the stage which holds the blade. To achieve a good clean section there must be absolutely no extraneous movement in any part of the mechanism that holds the chuck or the blade. All knobs, screws and levers securing of the knife, knife holder, chuck, chuck holder and microtome must always be tight and free of any debris that could cause movement. A simple bit of embedding medium on the back of the chuck, or beneath the blade can cause drastic changes in the cutting of the block.

There must be no movement in the system

The blade and every thing holding it must be tight.

-The blade must be completely inserted to proper depth. -Blade holder must clamp tight.

-Blade angle must be correct.

All clamping knobs holding knife holder and stage must be tight.

The specimen and everything holding it must be tight.

-Specimen must be secured to the chuck

-Chuck must be clamped tight.

-X-Y adjustment knob clamped tight

-Blade and chuck should be free of medium which could cause rocking or movement



Wrestling the fat one!

Fat is without question the arch nemesis of the frozen sectionist. It is a simple matter of nature that fat will not freeze. It can be made hard enough to cut thin sections at very low temperatures, but these temperatures are too cold for obtaining good sections of the non fatty tissues that are often present in the same sample. The problem will become obvious when the fat begins to smear and prevents cutting of any tissue in its path. I have had moderate success answering most of my questions in fat containing tissues using the following techniques.

1) Whenever possible dissect off any unnecessary fat from the tissues.

When I examine lymph nodes I am very meticulous about removing all of the fat from the surface and medulla if present. By pulling and scraping the fat off of the node using a scalpel and then slicing the fat away at the capsule line I am able to remove the fat without incising the lymph node capsule. There are those that will say I have removed tissue that may make me miss a positive node. It is my rational that I have a much better chance of finding a positive node with a good clean section than of a smeared miserable section containing a lot of fat.

The Fat Gouge Trick You can even remove fat after you have started to trim the block. A frequent problem in sentinel lymph node frozens. If an area of fat appears in the section as you are trimming down and is preventing you from a clean section see you can remove the fat using this technique. Described under "Plastering" below.

2) Orient the tissue so that fat hits the blade last or by itself as I described above.

Avoid having the fat hit the blade first if possible. The fat will pull away from the embedding medium and start a hole, If a little non fatty tissue is next to the embedding medium it gives it a little better bind to the medium and a better start to the section.


3) Start with a clean stage and a very cold block.

The stage and blade must be clean. If you smear a section it must be cleaned again with a dry gauze.. Be very careful of the blade. If you see streaks in the tissue or it begins to bunch there may be tissue stuck to the underside of the blade. Remove it and clean it very carefully.

The colder the block the easier to cut fat. Unfortunately the non fatty tissues will become harder and more difficult to cut. Watery tissues will shatter. It may be worth combining sections taken colder to optimize the fatty portion and somewhat warmer to optimize the non fatty portion. By following the technique I have outlined I am usually able to get a satisfactory exam by cooling it to the -24C temp of the well bars. Freezing sprays can be useful but beware of a snowstorm in a filthy cryostat!

4) Here is where the clean swift turn of the wheel without hesitation is most important.

If the tissue is a mixture of fat and connective tissues it will cut better than pure fat. Sometimes surprisingly well if you follow all of the techniques I have mentioned. Catch the edge of the tissue in motion and quickly and pull the section across the stage with the brush. Do not press the brush and tissue against the stage. It will stick and you won't be able to cut anything until you clean it. A good sharp blade will help. If you can make this swift cut you will be able to get reasonable sections of some fairly fatty tissues. The fat may appear as large empty spaces but the fibrous strands between them will be cut well. In that piece of breast tumor and margin where there is a few mm of fat which is covered by ink if you orient the fatty margin perpendicular to the blade, the tumor will cut fine, the fat will cut to varying degree and leave some empty space but there will often be a line of ink to indicate the position of the margin. A good swift clean section will show the strands of fibrous tissue that extend to the margin. I have found carcinoma in a fatty margin this way on a number of occasions.



1) Breast tissue with inked fatty margin.

2) Orient tissue so margin hits perpendicular and the fat hits the blade alone

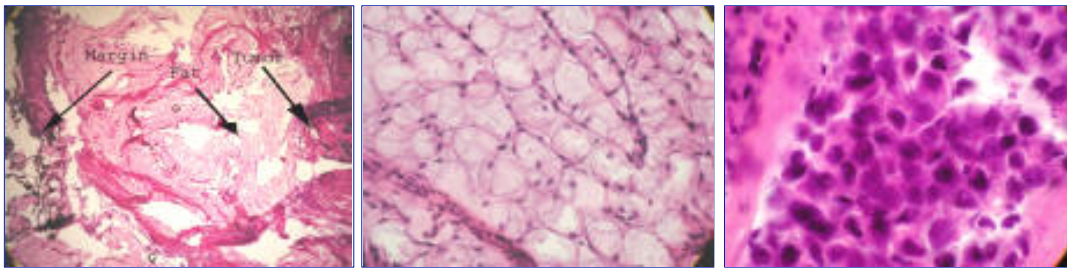
3) A smooth even turn of the wheel results in a clean section.

4) Here there are holes left where pure fat was present, yet the section is intact and the margin is interpretable.

5) Try a thick section in very fatty tissues

Taking thicker sections can be a good adjunct to reading your best attempt at a thin section. Thicker sections can be made by in a variety of ways. On my automated cryostat I first try with a single press of the fine advance button. If conservation of tissue is not an issue I may try a press of the course advance this will produce a very thick section. You can also adjust the section thickness dial or take a double click of the wheel by cranking

forward a quarter turn, then backward, and again forward. This variety of maneuvers will produce a range of section thickness. If you then turn the wheel in a continuous very deliberate fashion while using your best brush technique, you can end up with a slice of butter to pick up on the slide. Follow all the steps in fixing and staining but double or triple the times depending on the thickness. Be very gentle with the tissue in the solutions. No vigorous movements. For all this effort you will be rewarded with an amazing fairly well stained three dimensional section which you can actually see through because the fat is so transparent (Figure 16). You will see tiny capillaries coursing in all directions. I have also had luck recognizing structures in the non fatty portions. This type of preparation of a margin will contain the entire tissue face and can help interpret the thin section taken from a fatty margin where some of the tissue has been lost. Highly malignant nuclei and necrosis of a comedo carcinoma are still recognizable in these preparations. But realize if this is precious tissue you will be using it up quickly if you take more than two or three tries. Practice with a piece of fat before trying that breast margin.



- 1) Thick section of fatty tissue. Relationships and architecture preserved. 20x
- 2) Thick section of fatty tissue 200x. Can read through clear fatty cells.
- 3) Duct carcinoma in situ. Thick but still interpretable in conjunction with thin section above.

Plastering Technique *Basic block repair*

Plastering is a very simple and rapid way to address problems caused by defects in the block. In the section on details in face down embedding I discussed the first example below. When embedding tissues "super flat" with a very thin film of embedding medium on the dispensing slide, there will be a slight retraction of medium away from the tissue. If one needs to take a section with minimal trimming (in the first few hundred microns) the retraction space must be "plastered" with medium. If not, when the section is cut the tissue will separate from the medium making it difficult to get an intact section without having the tissue "curl away" from the medium. This simple maneuver takes only a second and results in a neatly filled block face. This is illustrated in the first example.

Plastering "super flat" embedded specimen




- 1) Close up of a flat embedded block showing slight retraction of medium around the tissue.
- 2) Place a drop of embedding medium on the chuck face.
- 3) Press the block face to a flat freezing surface such as cryostat stage or any of the freezing apparatus.
- 4) Remove the chuck with a tap of the over chuck freezing block.
- 5) Trimmed block with defects filled.

Plastering can be used to repair defects in blocks in a variety of common predicaments **Removing a staple**

In our practice we frequently get a variety of specimens riddled with staples. Every now and then one gets a way in the

gross and ends up in a block. It will make a real mess of the knife blade and your section will be split in two. Here is an easy way to deal with them.



- 1) Staple in the tissue. This is a mock up using a much larger paper staple. The technique is the same. ***Remove the blade while performing any of these maneuvers.***
- 2) Grab hold of the staple with a forceps or hemostat.
- 3) Rotate the hemostat and pull the staple out by rolling the staple on the tip of the hemostat.
- 4) A drop of embedding medium is placed on the defect. Embedding medium can be applied directly from the bottle or with a slide.
- 5) Press the over chuck freezing block against the block face.
- 6) & 7) The repaired block before and after trimming.

Removing a suture

Similar to removing a staple. The black silk suture shown here will not do too much damage to the section and may not need this procedure. The chromic and proline sutures can cause the section to split in which case it is worth pulling them.



Same basic technique as above. **First remove the blade.** The hemostat is best for grabbing the suture. **The "Gouge"**

This technique can be used to remove tissues which are not needed and are preventing us from obtaining a high quality section. The best example is fat interfering with the cutting of the section. This is a common problem in lymph nodes removed to evaluate for metastatic tumor. If fat hits the blade in front of the more manageable tissues you can first try rotating the block. If this is not a solution we can "gouge out" the fat or unwanted tissue and plaster over it. **Remove the blade first.**



The sample is a piece of skin and subcutis rolled in a circle. Fat is in the center. When cutting the tissue (picture 2) there is a central hole. Picture 3 shows "gouging out" of the fat in the center. Here I am using a home made spatula. Any DULL implement with a narrow tip can be used. A narrow tipped spatula or butter knife or would work fine.

For very precise gouging it may be easier to scrape the unwanted tissue away with the chuck in your hand and using a finer scraping tool. **Just be careful not to "gouge" your hand!**

Plaster the defect as above (picture 4). Picture 5 show the repaired block. Notice I am using two hands to best steady the implement while gouging.

Thoughts on the conservation of tissue.

When asked to perform a frozen section on a small sample the pathologist is often faced with the decision of how much tissue to use for the frozen section and how much to save for permanent sections. I take a very practical approach to this situation.

The decision is based on the reason for the frozen section.

Decision dictates the course of surgery

I will make every attempt to provide the necessary information while preserving some unused tissue. If it is a diagnosis that can be made on an H & E preparation I will use every possible measure to prepare a section of the quality of a permanent section. I am never hesitant to ask the surgeon for more tissue. If it means doing something risky they will usually not go further unless the circumstances are extreme. They may seem a bit cranky when asking for more tissue but they are a lot crankier the next day when you tell them that you do not have diagnostic tissue. We are doing them a service by assuring that they have an adequate sample to justify their surgery.

Surgery was performed is to provide diagnostic tissue

I will examine the least amount of tissue necessary to assure that the surgeon has provided diagnostic tissue. If my initial frozen section does not yield this information I will examine more and ask for more if necessary. If at anytime the surgeon tells me he cannot get more tissue I will examine only what I need to decide further disposition of the tissue such as flow cytometry, snap freezing a sample, culturing, or genetic studies.

Experience has taught me another cold fact. If I have sampled the tissues carefully and the specimen was insufficient for diagnosis on frozen section, it very often will be insufficient on permanent sections. I try not to leave the frozen section suite without a good sample of diagnostic tissue.

Touch preps, crush preps and smears.

These simple techniques provide extremely useful information to contrast with the findings in the frozen section particularly when examining neoplastic tissues. Smears provide a dimension of information that cannot be seen in sectioned tissue either on permanent or frozen section. Smears tell us something about the cohesive nature of the tissue. A lymphoma will dissociate into single cells where epithelial tissues will demonstrate cohesion. Some tumor cells such as small cell carcinomas demonstrate great nuclear fragility. Some tumors have delicate cytoplasm and yield naked nuclei on smearing. Connective tissue tumors and glial tumors will demonstrate important clues in the fibrillarity of the cytoplasm. By air drying slides and performing the diff quick stain a entire new compendium of cytoplasmic details appear including vacuoles, cytoplasmic and extracellular mucins and colloid become apparent. These preparations also provide the nuclear detail to fill any void that may be obscured in the frozen section.

In the seventh Addition of Ackerman's Surgical Pathology, Juan Rosai (1) the frozen section is described as "one of the most important and difficult procedures a pathologist performs during his practice. It requires experience, knowledge of clinical medicine and pathology, the capacity to make quick decisions under pressure, good judgment, an attitude that is conservative but not excessively so, and a keen awareness of the limitations of the method". Well, what are these limitations? The Manual of Surgical pathology (2) in a section titled" Frozen Sections Are Not Permanent Sections" points to four reasons. These are: sampling error, ice crystal artifacts, lack of special studies, and lack of consultation.

I would like to discuss what I consider the limitations in frozen section. I will divide these into two categories. True limitations I consider insurmountable limitations by virtue of the technique and constraints placed on it by the urgency of the procedure. Avoidable limitations I consider handicaps that we are forced to deal with but can be minimized to a degree where our ability to provide the diagnostic information can potentially match that of permanent sections.

True limitations:

1) **Time** - There is no question that in the frozen section room there is often pressure to quickly come up with an answer. **In my experience the best ways to make a mistake are to be rushed or interrupted.** Our best defense is confidence, and good rapport and education of our surgical colleagues. When pushed to speed up a frozen section we should resist this pressure at all costs. If you are a well trained and skilled frozen sectionist, the time to cut and stain a slide will be only a few minutes. If you are the pathologist grossing the tissue this process can take from a few minutes to 10 minutes or more for a large complicated specimen requiring multicolor inking. For the pathologist reading the slide, this can vary from seconds to 10 or more minutes if you are searching for some minute clue, paging through books or consulting colleagues. We must be practical and consider our surgical colleagues, but on the other hand, if this frozen section was requested for the proper reason we are asked to make a decision that will alter the course of surgery. We owe it to the patient to try our best to provide a correct answer, even if it is delaying the case a few extra minutes. It is far less costly than a re-operation or providing a wrong answer. If we are swamped with a barrage of cases, complicated cases or numerous specimens, the best we can do is ask for help. If any of the multitudes of specimens is not going to influence a surgical decision, then these should be put to the end of the line or not done at all. Try not to cut corners on the grossing, preparation and reading of the slides. This is where your errors will be born. One thing experience teaches you is to recognize a situation beyond your ability. In many of the cases in which I seek outside consultation, I know I'm stumped in the first few minutes of seeing the slide. It's like seeing an animal in the zoo for the first time. You're pretty sure you have never seen that in your backyard before. When faced with these cases I ask for whatever help is near. My advice is to tell your surgical colleagues all that you can be certain of and let them know they will have to be patient.

2) Limited special stains and studies - This is hard to argue with. Lets face it, in this day and age it would be malpractice try and sub classify lymphomas, sarcomas and all the things that mimic them without a few hardy trays full of immunoperoxidase stains and inspection of every twisted gene! Maybe the future will bring us more rapid studies that we can use at frozen section. As for now, this is a true limitation.

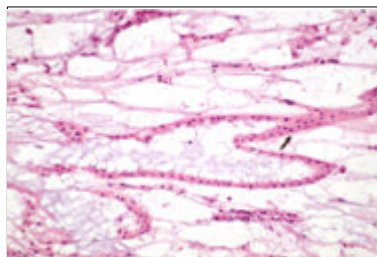
3) Lack of consultation - We are often alone in the frozen section room, with only our books to help us. Those of us in with large practices have the luxury of consultation with colleagues during working hours. The luxury of world expert consultation only an overnight express mail away is not an option. Or is it? At the present telepathology systems are being used to provide remote diagnostic services to distant hospitals. What began slow limited technology is now developing into an efficient practical means of outside consultation. I predict in the future that we will see telepathology develop into a widely used tool providing immediate intra-operative pathology consultation.

4) Freezing artifacts - It is a chemical property of water, that water will expand on freezing due to formation of hydrogen bonds. It is for this reason that ice floats. If it were not for this property the oceans would freeze over and we would not be here to think about it. Anyone who ever forgot a beer cooling in the freezer saw this principal in action. I believe the changes we see in tissues which are frozen are related to this expansion of water upon freezing. I will try to illustrate the differences between slides prepared by frozen section and those prepared by paraffin embedding.

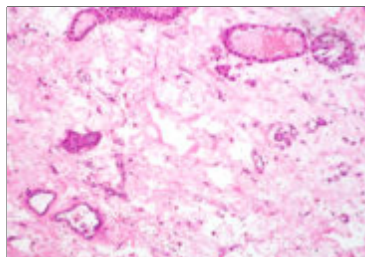
Like any artifacts we deal with in pathology, recognizing the artifact allows us to "read around them" so that we can make the correct interpretation.

Below are phenomena which I believe are artifacts of freezing.

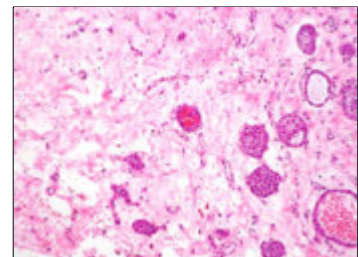
Ice Crystals ("bubbles") in edematous stroma. Very edematous tissues freeze with an appearance similar to soap bubbles. I believe as the water freezes the expanding water forms rounded ice crystals which compresses the strands of fibrous tissue giving appearance of bubbles (Lower left) The frozen control shows that as the tissue is processed these "bubbles" of water redistribute into the stroma. The tissue in the right was never frozen and shows by comparison the edematous nature of the stroma.



Frozen Section



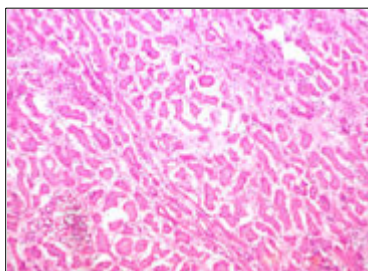
Frozen control



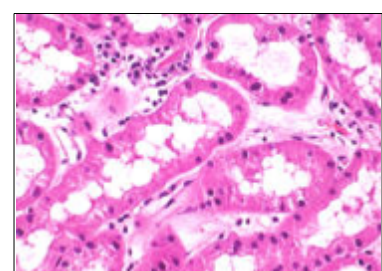
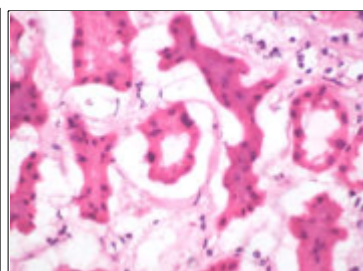
Not frozen

These very edematous tissues can be difficult to cut without shattering due to the icy consistency. These tissues be **as warm as possible** to get a clean section.

Compression Artifacts Cellular tissues will be compressed by expanding ice bubbles. This is most evident in edematous tissues. The example of the kidney parenchyma below demonstrates an extreme example of this phenomenon. The center picture shows the renal tubules being compressed by the clear ice crystals. The picture on the right shows tissue which was never frozen.



Frozen section

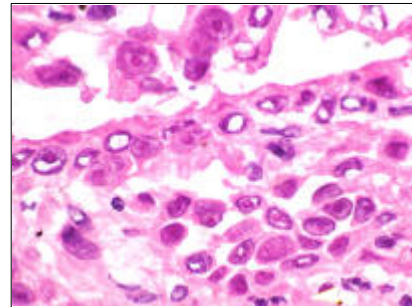
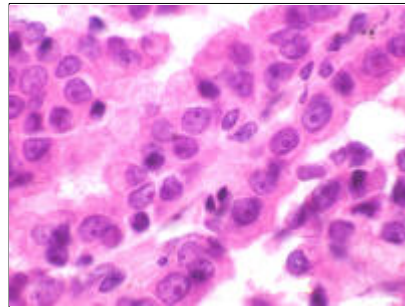


Not frozen

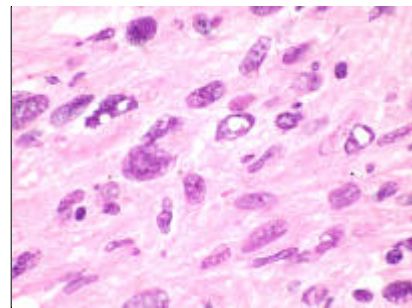
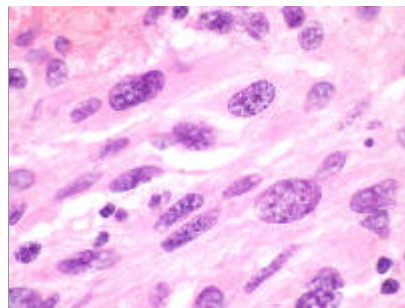
Nuclear ice crystals Nuclei will show varying tendency to form ice crystals. From my observations this seems to relate to the type of tissue as well as the state of the tissue. I have noticed more of these crystals in damaged tissues. It makes sense that tissue which are damaged by cautery or ischemia would have loss of osmotic homeostasis and might therefore result in more "nuclear edema". It also seems that the more vesicular nuclei have greater tendency to show these ice crystals. I have made one very important observation:

The thinner the tissue is cut the more these crystals appear as holes! The examples below clearly illustrate this point.

Lung Adenoarcinoma



Uterine Sarcoma

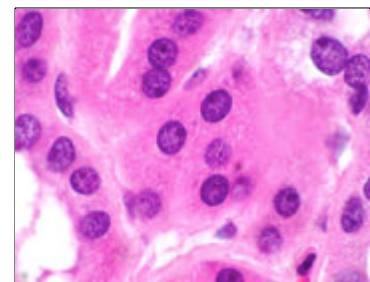
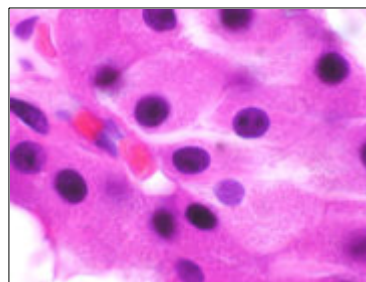
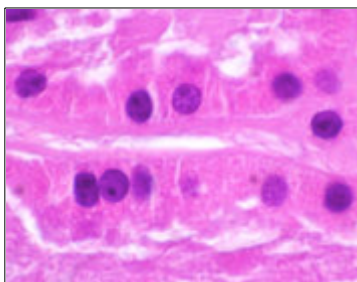


6 Microns

3 Microns

As I mentioned earlier some times even if our cryostat is set for 6 microns we will get "thin sections" which actually are much thinner. This will explain why sometimes these crystals are more numerous.

Nuclear chromatin changes in frozen control. The example on the right below demonstrates the chromatin in this previously frozen tissue. The chromatin is somewhat more condensed and hyper chromatic than the frozen section on the left which has been fixed rapidly. Notice the more vacuolated cytoplasm in the frozen sample, another very subtle example of freeze artifacts



Frozen section

**Permanent section
previously frozen**

**Permanent section never
frozen**

Avoidable limitations:

1) Drying artifacts - A great deal of the nuclear artifact that I see in frozen sections is a result of "drying artifact." Just as the cells of an air dried diff quick stained slide have features of smudgy poorly defined chromatin, the nuclei of a frozen section left for more than a few seconds to dry show a loss of definition. A slide that can be fixed in a second or two in this time will show nuclear detail that rivals good cytology preparations. The exception to this will be the very vesicular nuclei which will retain their empty appearance which I consider a freezing artifact. (See frozen section technique page)

2) Sampling error - *One of my favorite questions to my residents is "What is the most important thing we do in the frozen section room?" The answer is "The gross".* It does not matter how perfect our slide turns out if we have sampled the wrong part of the tissue. I insist that the process of grossing in the frozen section room should be performed in a meticulous systematic fashion. If I handle a breast biopsy or other solid tumor all external aspects should be observed and palpated carefully before inking. Then after inking, slicing or dissection is performed. The specimen is laid out in an orderly fashion. Then starting from the first slice, the tissue is examined with the eyes and palpated with the fingers slice by slice. Complex organs are examined by anatomic regions. One must be careful not to jump to the obvious nodule in one of the central sections because by doing this surely one day they will miss the 3 mm nodule at the edge. Another piece of advice to my residents is *"When your looking at a specimen if you cannot smell the tissue you are not looking close enough."* If the surgeon is only supplying us with a small portion of tissue, then there will be sampling error (his), but this will apply equally to the permanent section. With a good gross examination the only sampling errors will be dictated by how many sections we have time to sample and cut. This is really the limitation of time and what's practical.

3) Fat - The yellow monster. This greasy guy just does not freeze. But there are approaches to deal with him that can help us through most situations. I was not sure which category to place fat. By virtue of the laws of chemistry and physics this is an inaqueous material which does not freeze. But if our real purpose of freezing tissue is to harden it so that it may be cut thin. And in fact at very low temperatures this material does harden. BUT at that temperature the tissues we are interested in will shatter. It is unquestionably our supreme nemesis in the cutting of frozen sections and will always be a handicap.

4) The quality of the section is inferior - In the hands of an artist a frozen section can be cut and stained with the quality of a permanent section. If it's fixed quickly as I have described above the cytology can be preserved as well. Is the technique of frozen section to blame, or the inconsistent way it is taught? Can we blame a poorly stained slide on the stain or the person who stained it. Can we blame a wrinkled and shattered section on the technique or the technician? This brings us to the next avoidable limitation.

5) Inconsistency of training and performance - There is a great deal of inconsistency in the training of frozen sectionists, be they histotechnologists or pathologists. There is inconsistency in who performs different parts of the task. Is the pathologist selecting the sections and dictating the approach to embedding? Is it a resident? A pathology assistant? A histotechnologist? I mentioned above that I believe the gross to be extremely important. Even in a small sample, failing to recognize a minute gross detail could create an error due to poor embedding. A large complex specimen needs to be systematically examined by a pathologist without question. Once embedded, the frozen should be cut and stained by a properly trained individual. But again there is considerable variability in the training of these individuals.

6) Embedding - This is a great limitation to the conventional methods of preparation of frozen sections. We may be asked to balance an icicle on the head of a pin. To accomplish this cryostats offer us a piece of steak on a tin plate and precede to squashes it with a hammer! Using conventional methods we may be asked to attempt to prepare precious minute tissues that may later disappear into a snowstorm. Up until now this is where the wizards had to resort to their magic. Through tedious and time consuming manipulations tissues are teased into various best attempts. The techniques I have offered in this web site will rapidly prepare blocks with a level of precision that surpasses paraffin embedding. I have resorted to using my limited artistic ability to demonstrate the level of facility and precision capable using these surprisingly simple techniques.

Conclusion

One must know what excellence looks like and sounds like in order to begin to approximate it. In all forms of art one can only achieve excellence if they are aware of all the ways to make mistakes and are aware when they are happening. SP

In this discussion I have attempted to provide a detailed fund of information which would offer operator a technical method to prepare high quality frozen sections. I have also tried to provide the details necessary to distinguish problems as they were arising and solutions with which to approach them. These are the techniques and

observations I have gained in my experience. I have no doubt that there are many experienced pathologists and histotechnologists who have a multitude of valuable observations and techniques which remain unshared. It is my hope that others will be stimulated by these writings to present their own unique methods. My intention in these writings is to offer a nidus of information for colleagues to add to or criticize.

Note to readers: These techniques are mostly based on my own observations in my practice. Anyone who has anything to add, suggestions to improve on this discussion or disagrees with any part of it please Email me at petepath@yahoo.com. I will be happy to add useful information and credit the contributor. SP

1. Rosai, J. Chapter 1 Introduction, In: Ackerman's Surgical Pathology seventh Ed. Mosby, 1989:8-9.
2. Lester,SB. Chapter 6. Operating Room Consultations, In: Manual of Surgical Pathology. Churchill Livingstone, 2001:

Addendum

Tissue specific temperatures

Tissue type	Chamber temperature	Specimen head temperature
Spleen	-15 °C to -20 °C	-11 °C
Liver	-10 °C -15 °C	-20 °C off until -15 °C
Intestine	-10 °C -15 °C	-20 °C A*: off until -20 °C E*: -20 °C
Heart	-10 °C -15 °C	A: -20 °C E: -20 °C to -30 °C off until -20 °C
Ovaries	-10 °C -15 °C	E: -20 °C off until -15 °C
Fallopian tube	-10 °C -15 °C	E: -20 °C off until -15 °C
Kidney	-10 °C -15 °C -20 °C	-20 °C A: off until -15 °C -20 °C
Muscle	-18 °C to -20 °C	-15 °C
Skin with fat	-19 °C	-32 °C to -40 °C
Hard fat	-19 °C	-21 °C to -25 °C
Stomach	-10 °C -15 °C	-20 °C off until -15 °C
Brain	-15 °C	-10 °C, *E

***A = blocked, *E = complete**

The temperature values given in this table are based on experience, however, these are only approximate values, as any tissue may require particular adjustments.